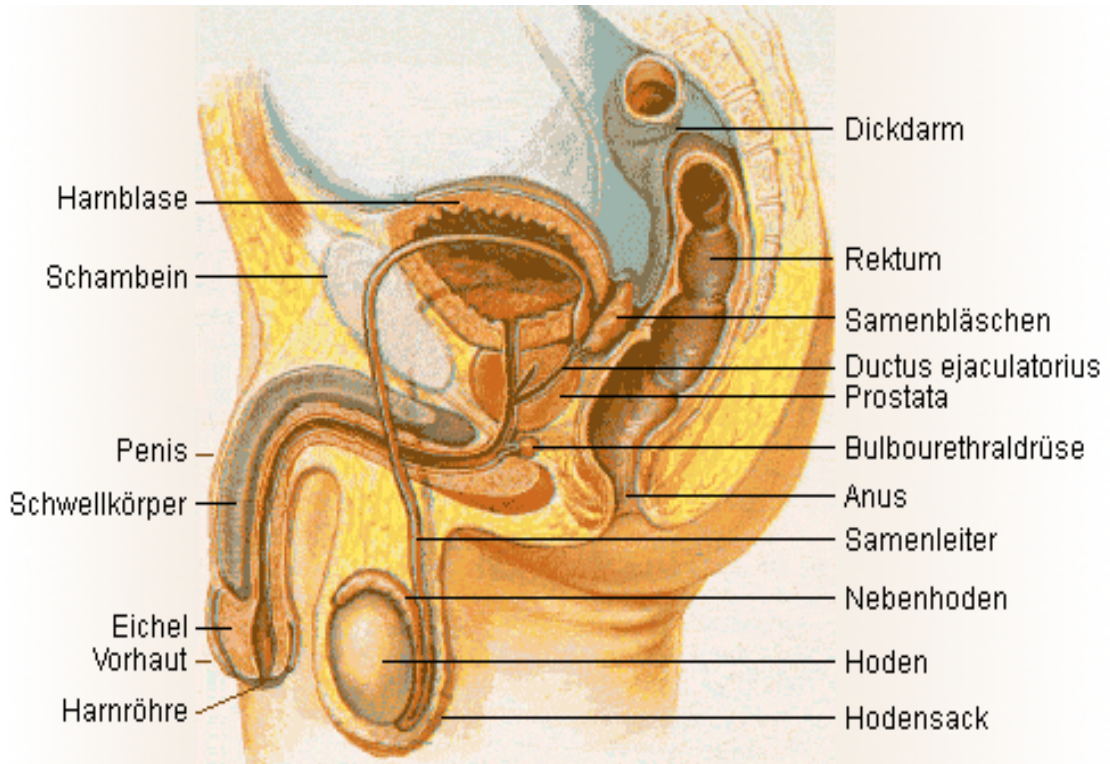


Illustrative material:



(Source: Wikipedia)

Urinary bladder	Colon
Pubis	Rectum
Penis	Seminal vesicles
Corpus cavernosum	Ejaculatory duct
Glans	Prostate
Prepuce	Bulbourethral glands (Cowper's gland)
Urinary meatus	Anus
	Deferent duct
	Epididymis
	Testicle
	Scrotum